

# optomap®

## DETECTS PERIPHERAL LESIONS

### ASSOCIATED WITH NEARLY 5 FOLD RISK OF PROGRESSION

optomap

**The presence of predominantly peripheral lesions was associated with an almost 5 fold risk in the progression of diabetic retinopathy (DR) over 4 years.<sup>1</sup>**

**A study published in Ophthalmology finds 50% of diabetic lesions located outside the area of ETDRS Gold Standard area.<sup>2</sup> These lesions might result in a more severe grade of retinopathy in 13% of eyes.**

- The results of several clinical studies comparing **optomap**® ultra-widefield (UWF™) images have indicated there is substantial agreement with Early Treatment Diabetic Retinopathy Study (ETDRS) 7-standard (ETDRS) film photographs and dilated fundus examination in determining diabetic retinopathy severity.<sup>1,2,3</sup>
- Predominantly peripheral lesions identified in up to 50% of eyes using **optomap** suggested a more severe assessment of diabetic retinopathy in 13% of eyes.
- The presence of predominantly peripheral lesions was associated with the progression of diabetic retinopathy (DR) over 4 years, independent of baseline severity and HbA1c.<sup>4</sup>
- One study found that **optomap** is superior at identifying high-risk PDR.

*“The presence of DR lesions located predominantly in this peripheral area seemed to identify a subset of eyes at greatly increased risk of DR progression and onset of PDR...the rigorous evaluation of the peripheral retina may become an essential and routine component of accurately characterizing DR severity, and thus may prompt a revision of the ETDRS grading algorithms to best optimize the association of DR severity grade and clinical outcome.”<sup>1</sup>*

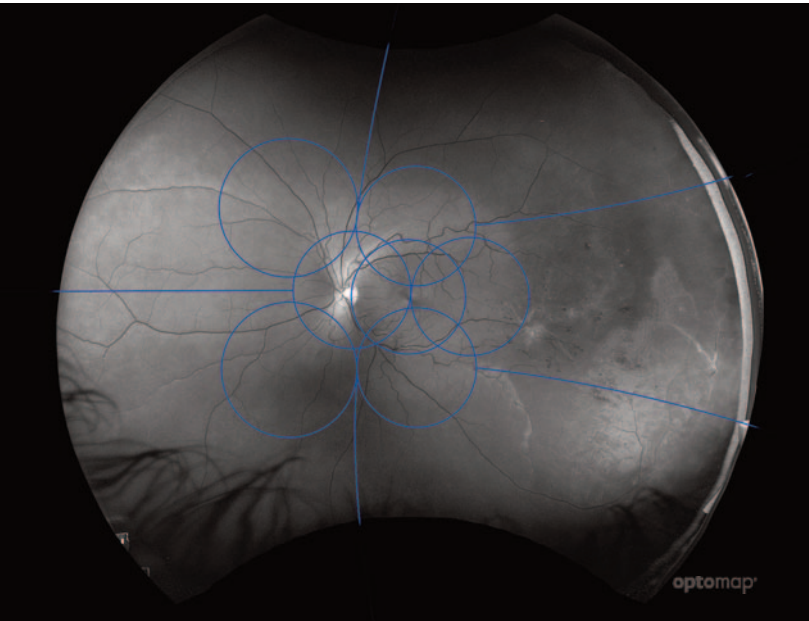
— Ophthalmology, 2015

See how **optomap** will help you manage your diabetic patients. For more information call **800-854-3039** or email **BDS@optos.com**.



# CLINICAL SUMMARY

## optomap Detects Peripheral Lesions Associated With Nearly 5 Fold Risk of Progression Over 4 Years



Comparison field of view between **optomap** and the area covered by a standard ETDRS montage.

- **optomap** images have been found to have substantial agreement with the gold standard Early Treatment Diabetic Retinopathy Study (ETDRS) film for the diagnosis and severity grading of diabetic retinopathy.<sup>1,2,3</sup>
- In addition, the latest study identified that 50% of the lesions were in the area outside of ETDRS and that in 13% of patients these lesions suggested a more severe grade of retinopathy.<sup>2</sup>
- The presence of predominantly peripheral lesions was associated with the progression of diabetic retinopathy (DR) over 4 years, independent of baseline severity and AIC.<sup>5</sup>
- Eyes with predominantly peripheral lesions (defined as outside of ETDRS 7 standard field) had a 4.7 fold increased risk of progression to proliferative diabetic retinopathy (PDR).<sup>4</sup>
- Eyes with predominantly peripheral lesions had a 3.2 fold risk of 2 step progression in DR.<sup>4</sup>

1. Peripheral Lesions Identified on Ultrawide Field Imaging Predict Increased Risk of Diabetic Retinopathy Progression over 4 Years. Ophthalmology 2015.  
2. Hemorrhage and/or Microaneurysm Severity and Count in Ultrawide Field Images and Early Treatment Diabetic Retinopathy Study Photography. Ophthalmology. 2017.  
3. Evaluation of a new model of care for people with complications of diabetic retinopathy: The EMERALD Study. Ophthalmology. 2020  
4. Nonmydriatic Ultrawide Field Retinal Imaging Compared with Dilated Standard 7-Field 35mm Photography and Retinal Specialist Examination for Evaluation of Diabetic Retinopathy. American Journal of Ophthalmology. 2012  
5. Peripheral Lesions Identified by Mydriatic Ultrawide Field Imaging: Distribution and Potential Impact on Diabetic Retinopathy Severity. Ophthalmology. 2013



**Optos plc**  
Tel: +44 (0)1383 843350  
ics@optos.com

**Optos, Inc.**  
Tel: 800 854 3039  
Tel: 508 787 1400  
usinfo@optos.com

**Optos Australia**  
Tel: +61 8 8444 6500  
auinfo@optos.com

