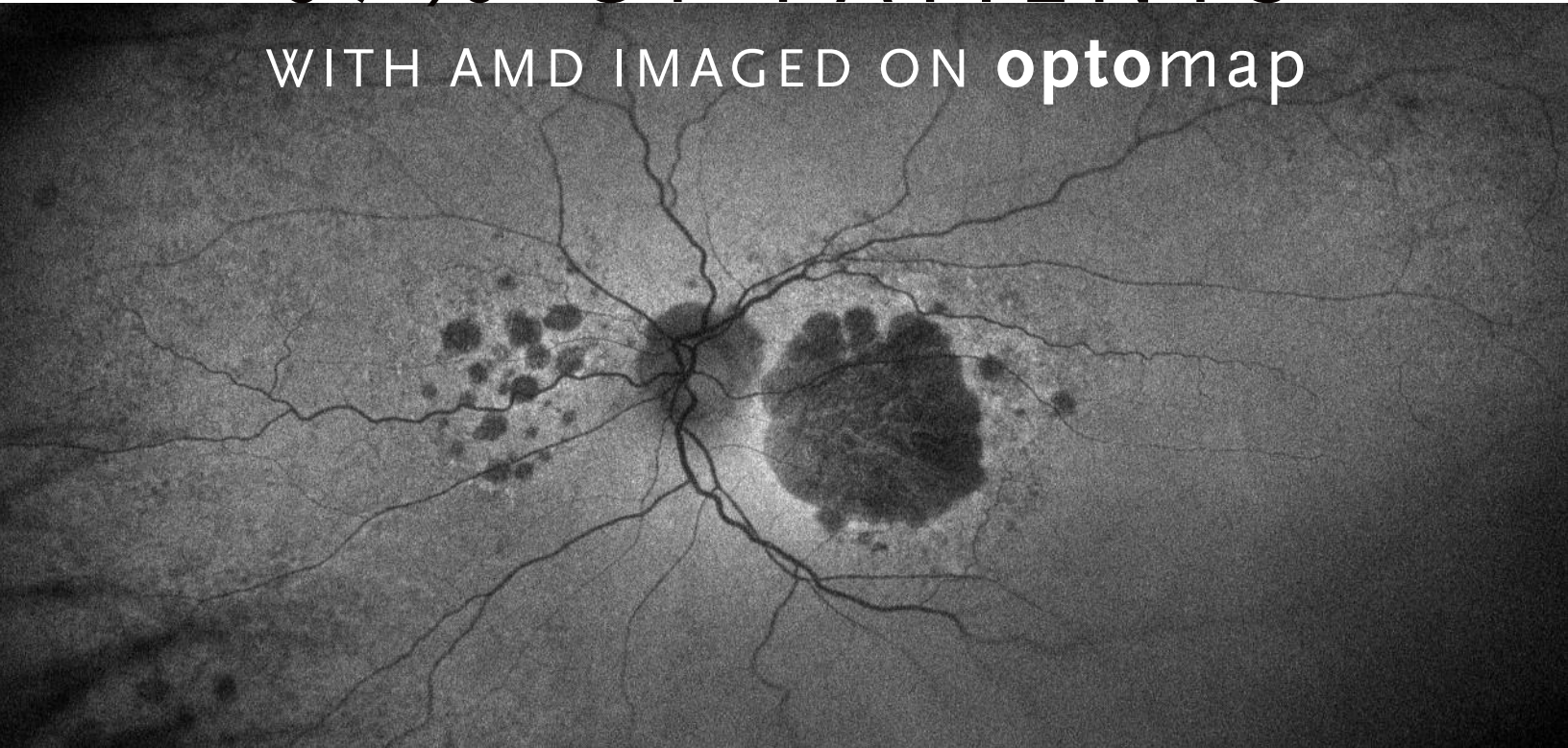


PERIPHERAL CHANGES FOUND IN 67% OF PATIENTS WITH AMD IMAGED ON **optomap**



A study published in Ophthalmology found that optomap® confirmed the presence of wide-ranging AMD-like pathologic changes even in those without central sight-threatening macular disease. 67% of patients with age-related macular degeneration (AMD) had peripheral retinal changes associated with AMD.

Results from a recent clinical study published suggest that ultra-widefield color and autofluorescence (*af*) imaging confirmed the presence of wide-ranging AMD-like pathologic changes in subjects with AMD even in those without central sight-threatening macular disease. The overwhelming majority of subjects investigated were determined to have hard, crystalline, and soft drusen; retinal pigment epithelial changes; choroidal neovascularization (CNV) and atrophy evidenced by hypoautofluorescence and hyperautofluorescence in the peripheral retina.

“Peripheral retina grading may be important for the fuller understanding of the development and progression of AMD and potentially other diseases”

— Ophthalmology 2015

See how **optomap** will help you improve the way you manage your patients.

For more information call **800-854-3039** or email **BDS@optos.com**

Building *The* Retina Company



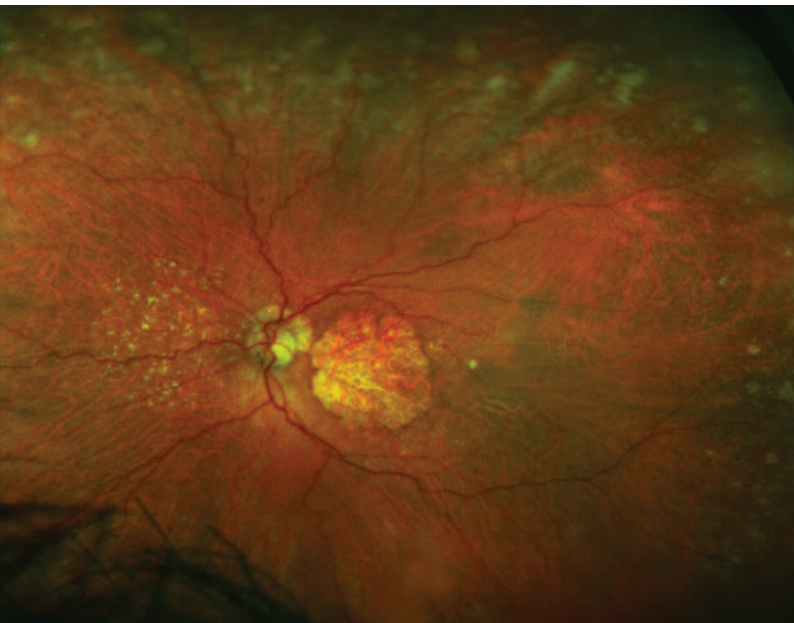optos.com

CLINICAL SUMMARY

A Population-Based Ultra-Widefield Digital Image Grading Study for Age-Related Macular Degeneration-Like Lesions at the Peripheral Retina

Lengyel, Csutak, Florea, Leung, Bird, Jonasson, Peto
Ophthalmology | 2015

The 12 year follow-up for subjects in the Reykjavik Eye Study in Iceland were evaluated with **optomap** color and autofluorescence imaging. Phenotyping the retinal periphery using the categories defined by the International Classification confirmed the presence of wide-ranging AMD-like pathologic changes even in those without central sight-threatening macular disease. Authors propose new, reliably identifiable grading categories that may be more suited for population-based ultra-widefield imaging.



Color ultra-widefield **optomap** image demonstrating central-involved geographic atrophy with wide-spread peripheral changes.

- Of the eyes examined, 81.1% had AMD-like changes. 13.6% had AMD-like changes in the macula alone, 10.1% had changes in the periphery alone, 57.4% had pathologic changes in both periphery and macula.
- Seven patients had AMD-like atrophy in the periphery without end-stage disease in the macula while only one had end-stage disease in the macula but normal periphery results on the color images.
- Comparison of grading of macular abnormalities on ultra-widefield images with conventional digital fundus images (45°) showed no substantial differences between grading for AMD in the macula. Ultra-widefield images were gradable in the macula, even those that fell short of grading standards on conventional fundus images. This was because of the capacity of laser beams to overcome problems with media opacities and they have higher resolution in terms of sharpness and contrast than conventional color images.
- The median age for the patient population was 72 years old, subjects underwent 11 evaluations including traditional fundus photo imaging, only 1.2% of subjects were unable to obtain gradable ultra-widefield images
- The phenotypes associated with vast areas of the peripheral retina and were distinct from macular changes. Their association with early or late AMD in the macula should be investigated in follow-up studies.

Optos plc
Tel: +44 (0)1383 843300
ics@optos.com

Optos, Inc.
Tel: 1-800-854-3039
usinfo@optos.com

Optos Australia
Tel: +61 8 8443 4533
auinfo@optos.com



optos.com