

When 60 year-old Brian came to Belill Eye Care, in Clio, Michigan, he assumed he had more pressing concerns than his routine eye exam. Plagued for years with chronic back pain he finally had a surgery scheduled within the next two weeks to address that issue. He reported to the staff that he had no significant ocular issues, other than the fairly recent occurrence of floaters in his left eye. He also professed to have pressing affairs to attend to subsequent to his eye exam and he refused to be dilated. This caused Nicholas Belill, OD, some consternation

as Brian had a history of retinal tears and the report of floaters seemed cause for concern. Dr. Belill determined that it was not prudent to delay a thorough retinal evaluation until after Brian's back surgery, so he quickly obtained an **optomap** image using standard and eye steering functions. The superior steering revealed a large PVD inferior and a possible retinal tear at eleven o'clock OS.

"It's really pretty remarkable, here I had this patient with dark brown eyes, 3mm pupils,

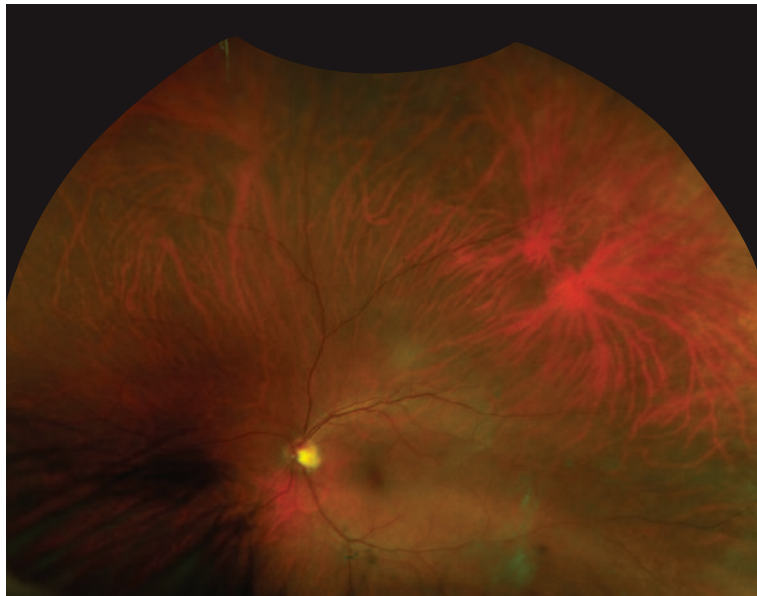
a history of retinal tears, reporting floaters and he is refusing dilation because he is in a hurry. It is Friday afternoon and I still need to make a diagnosis and management plan going into the weekend. With **optomap** and without dilation I was able to obtain an image of a very small, difficult to detect tear, far out in the periphery."

Belill reviewed the image with Brian and referred him immediately to a retinal specialist who confirmed the presence of the tear. Prior to treating Brian, the specialist

confirmed with the orthopedic surgeon that laser retinopexy could be safely administered so close to the scheduled back surgery.

*"It was pretty great finding that retinal tear in the periphery in a patient with 3 mm pupils who is refusing dilation." He added, "It's interesting, when the retinal specialist reported back to me that it was indeed a retinal tear, he also commented that it was so small and far out that he was impressed that optomap caught it."*

**Nicholas Belill, OD**  
Belill Eye Care  
Clio, MI



**optomap** color image highlighting both the retinal tear and PVD, both in the far periphery.

**Optos plc**  
Tel: +44 (0)1383 843300  
ics@optos.com

**Optos, Inc**  
Call Toll-free (US & Canada):  
1-800-854-3039  
Outside of the US: +1 508 787 1400  
usinfo@optos.com

**Optos Australia**  
Tel: +61 8 8444 6500  
auinfo@optos.com



Building **The** Retina Company



optos.com