

When 47-year-old Ruthie came to see Dr. Rachael Wruble in August 2019, she was intent on receiving an expedited exam and leaving with a new glasses prescription. She complained of blurry vision but because she had a busy day ahead, she refused dilation. Fortunately for her, at Belmont Eye all patients are encouraged to have an ultra-widefield (UWF™) **optomap** screening as part of their standard refractive exam. The **optomap** process allows the doctor to capture vortex ampullae in all four quadrants in a single-capture UWF image in less than ½ second through an undilated pupil.

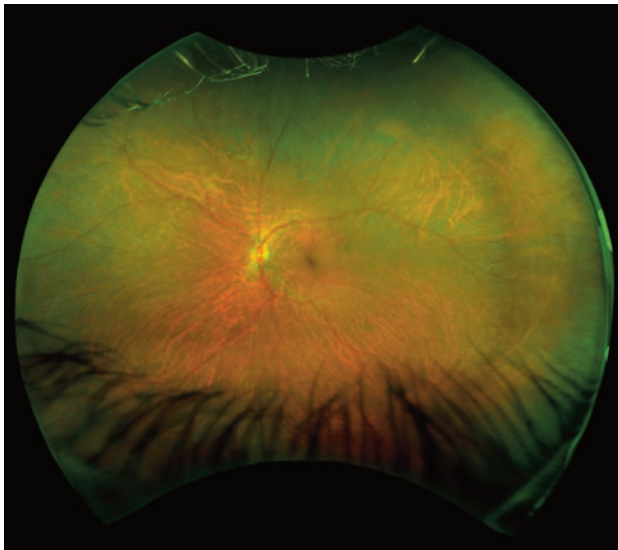
When Wruble pulled up the **optomap** image that day she saw immediately that Ruthie had branch retinal vein occlusion (BRVO) and swelling of the macula in the right eye.

“I showed her the image and explained that this was why she was having trouble with her vision,” says Wruble. “When I asked her about her blood pressure, she told me that had been taking Lisinopril but stopped taking it two weeks prior.” Wruble notes that at the office that day Ruthie’s blood pressure was 174/98. “Thankfully in our office a full health assessment is part of the exam. If only a refraction had been completed this issue might have been missed. With the **optomap** image I was able to actually show her what I was seeing and explain that this was not a problem that could be fixed with a glasses prescription. Showing her the **optomap** image made it more real for her and brought more awareness to her of how her systemic health and her eyes

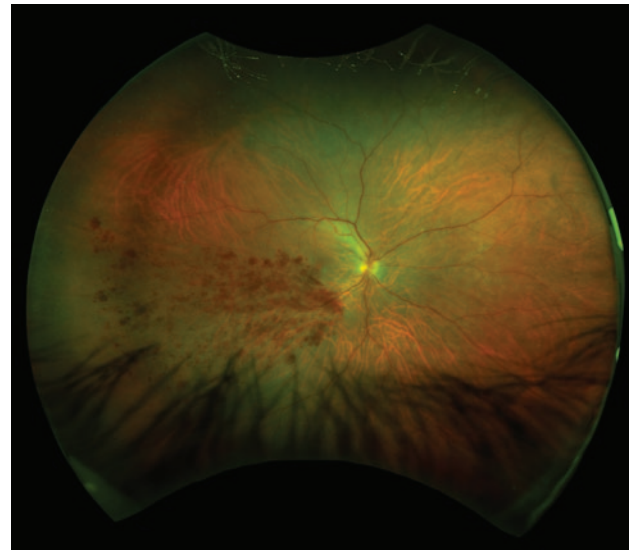
are related and how hypertension (HTN) can even lead to blindness.” Wruble notes that Ruthie’s refraction of 20/40 OS, 20/200 PH and 20/400 OD that day revealed how advanced the issue was already, and that Ruthie could be classified as legally blind. She underscores that **optomap** helped her to tangibly educate Ruthie on how, even at 47 years old, HTN and related blindness are a real risk. Wruble called Ruthie’s primary care physician to make them aware of the situation and she also referred her to a retina specialist for an injection. “She was extremely grateful and gave me a hug,” Wruble adds, emphasizing how Ruthie’s case was one scenario which secures the value of **optomap** imaging in her practice.

“ It really helps me to demonstrate to my patients what is occurring in their eyes. It also gives me tremendous peace of mind that I am not missing anything if patients refuse dilation, or with populations that are more difficult to examine by standard methods. optomap helps us provide a better patient experience. ”

Rachael Wruble, OD
Belmont Eye
Charlotte, NC



Healthy **optomap** image of Ruthie’s left eye



optomap image showing BRVO in Ruthie’s right eye



Optos plc
Tel: +44 (0)1383 843350
ics@optos.com

Optos, Inc.
Call Toll-free (US & Canada): 800 854 3039
Outside of the US: 508 787 1400
usinfo@optos.com

Optos Australia
Tel: +61 8 8444 6500
auinfo@optos.com

