

optomap® | PATIENT STORY LYNETTE

One week after purchasing his first **optomap** device, Anthony Clark, OD of Triangle Vision in North Carolina, experienced how utilizing **optomap** technology can help save lives.

Clark recounts how his 42-year-old patient, Lynette, came in for an eye exam and, despite being overweight and on blood pressure medication, she was in relatively good health and asymptomatic. "Everything was fine until I looked at the **optomap** images," Clark explained. "They revealed bilateral, temporal, peripheral dot hemorrhages - worse in the left eye." As Clark reviewed the image with Lynette, he explained to her what they were seeing and how this could indicate cardiovascular issues.

"Here is evidence of the power of **optomap** images in patient education. What I had seen in the image jumped out to me but more importantly it jumped out to her!" Clark explained how Lynette already had an appointment scheduled with her primary care provider, so he gave her a letter to accompany her to that appointment. Despite the fact that Clark's concerns were clearly outlined in that letter, the PCP reportedly dismissed the issue.

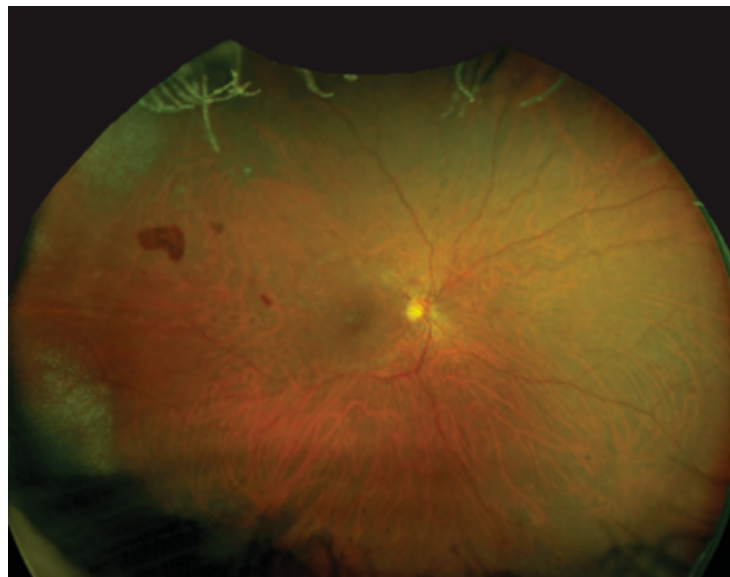
However, shortly thereafter Lynette saw a Public Service Announcement for free carotid arterial screenings. Remembering her **optomap** image, she responded to this opportunity at the local hospital.

There they discovered from the screening that she was 95 percent occluded on the right side and 80 percent occluded on the left side. She was immediately admitted and as she was being prepped for surgery she recalls that the surgeon remarked, "I don't know who found this, but whoever it was, saved your life." Lynette credits Dr. Clark and the **optomap** image for alerting her to the life threatening issue.

"I am excited for her," said Clark pointing out that Lynette is doing well following her treatment. "There is a dramatic improvement in her retinal appearance as well."

"You see, we want to help people and this technology helps me to help my patients more effectively. Lynette's story is a great story with a great result and it is just one great example of why optomap is so incredibly valuable."

**Anthony Clark, OD
Triangle Vision
North Carolina**



The **optomap** color image above, shows peripheral hemorrhages denoting a diagnosis of Retinal Vein Occlusion, similar to what the patient in this case, experienced.



Optos UK/Europe
+44 (0)1383 843350
ics@optos.com

Optos North America
800 854 3039
usinfo@optos.com

Optos DACH
DE: 0800 72 36 805
AT: 0800 24 48 86
CH: 0800 55 87 39
ics@optos.com

Optos Australia
+61 8 8444 6500
auinfo@optos.com



Contact us: