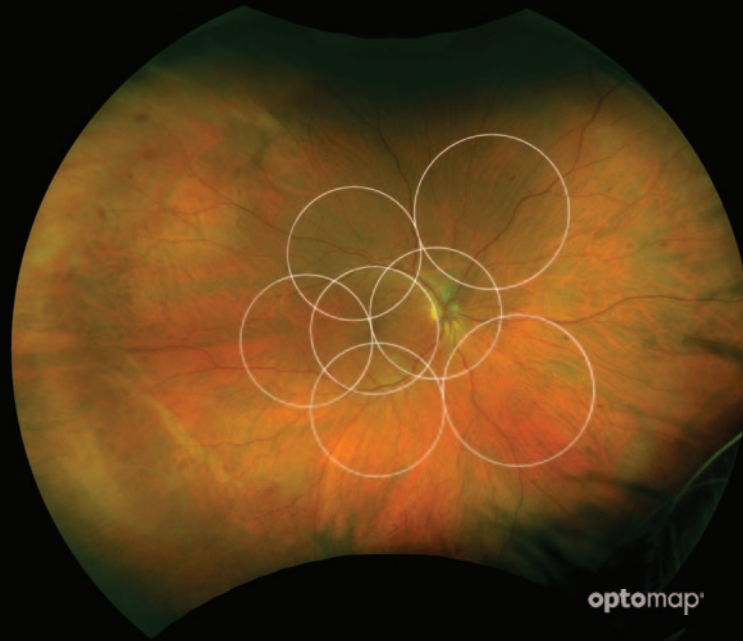

optomap

EQUIVALENT TO ETDRS



Results from several large multi-center collaborative studies confirm the equivalence of optomap® to ETDRS Gold Standard for grading diabetic retinopathy (DR).

- A study of over 700 eyes at 38 sites has demonstrated ultra-widefield (UWF™) imaging has moderate to substantial agreement when determining DR severity within the area covered by Early Treatment Diabetic Retinopathy Study (ETDRS) 7-standard field.¹ The results of several studies comparing **optomap** images have indicated that there is substantial agreement with ETDRS 7-standard film photographs and dilated fundus examination in determining diabetic retinopathy severity.^{2,3,4}
- When compared, the **optomap** and ETDRS images agreed exactly 59% and were within one level 97% of the time.
- Predominantly peripheral DR lesions (PPL) are present in up to 50% of these eyes and suggested increased DR severity by 2 or more steps in 11.0%.⁴
- A recent large multi-center trial has also found that UWF is superior to ETDRS at identifying high-risk PDR.⁵
- Another recent study found that implementing optomap into a screening program with patients previously treated for Diabetic Macular Edema (DME) helped improve efficiency and reduce cost.⁶

“The identification of a subset of eyes at greatly increased risk of DR progression and onset of PDR that cannot be assessed by ETDRS 7-field imaging would have significant implications for the evaluation and care of diabetic eye disease. Not only would UWF devices be the preferred imaging modality, but their use would be important in clinical trial settings requiring precise prediction of DR progression rates, in clinical care for accurate patient counseling, and in tele-ophthalmology programs to improve risk assessment and triage in eyes that otherwise would not have the peripheral retina evaluated.”

Ophthalmology 2018

See how **optomap** will help you manage your diabetic patients. For more information call **800-854-3039** or email **BDS@optos.com**

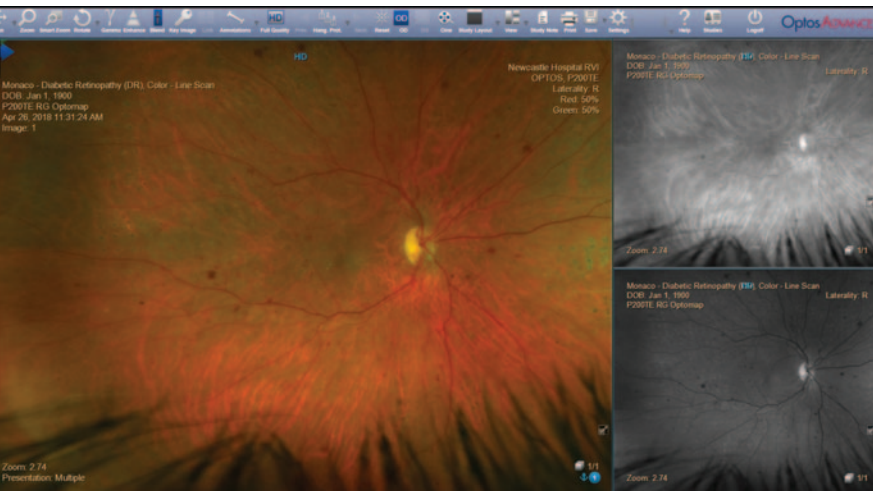


CLINICAL SUMMARY

Can Ultra-widefield Retinal Imaging Replace ETDRS for Grading Diabetic Retinopathy?

For two decades, the standard for determining severity of DR has been the extended modified Airlie House classification used in the ETDRS study where the location and extent of specific retinal lesions on 7 stereoscopic pairs of fundus photographs are evaluated in the posterior pole. The identification of these lesions was highly correlated with the risk of progression.

Many recent studies have reported on the value of UWF imaging for the identification of DR lesions in the retinal periphery.^{2,3,4,5}



optomap images can be evaluated using Optos Advance for DR lesions as a color composite image or the image can be separated into red and green channels to improve the visualization of individual lesions.

- ETDRS and UWF imaging have moderate to substantial agreement when determining DR severity within the central pole and UWF imaging can be used in place of ETDRS imaging for DR grading and management.¹
- UWF masked and ETDRS images after adjudication, determined 59.0% eyes had exact agreement and 96.9% were within 1-step.¹
- Predominantly peripheral DR lesions (PPL) are present in up to 50% of these eyes and suggested increased DR severity by 2 or more steps in 11.0%.^{1,4}
- UWF images were better for assessing DR level in 27% of eyes than ETDRS.¹
- A large multi-center European study confirmed the equivalence for UWF with traditional ETDRS imaging. Notably, it found that UWF was superior for high-risk PDR.⁴
- UWF imaging in clinical settings not only increases the frequency of diabetic retinopathy identification nearly 2-fold, but also reduces acquisition time, ungradable image rates and image evaluation time compared to nonmydriatic fundus photography.^{1, 6, 7}
- Previous studies have found that PPL were associated with an almost 5 fold risk in the progression of diabetic retinopathy (DR) over 4 years.⁶

References:

1. Comparison of ETDRS Standard 7-field Imaging versus Ultrawide Field Imaging for Determining Diabetic Retinopathy Severity. JAMA Ophthalmology. 2018.
2. Nonmydriatic Ultrawide Field Retinal Imaging Compared with Dilated Standard 7-Field 35mm Photography and Retinal Specialist Examination for Evaluation of Diabetic Retinopathy. American Journal of Ophthalmology. 2012.
3. Peripheral Lesions Identified by Mydriatic Ultrawide Field Imaging: Distribution and Potential Impact on Diabetic Retinopathy Severity. Ophthalmology. 2013.
4. Hemorrhage and/or Microaneurysm Severity and Count in Ultrawide Field Images and Early Treatment Diabetic Retinopathy Study Photography. Ophthalmology. 2017.
5. Evaluation of a new model of care for people with complications of diabetic retinopathy: The EMERALD Study. Ophthalmology. 2020
6. Surveillance of people with previously successfully treated diabetic macular oedema and proliferative diabetic retinopathy by trained ophthalmic graders: cost analysis from the EMERALD study. Br J Ophthalmol. 2021
7. Potential efficiency benefits of nonmydriatic ultrawide field retinal imaging in an ocular telehealth diabetic retinopathy program. Diabetes Care. 2014.
8. Peripheral Lesions Identified on Ultrawide Field Imaging Predict Increased Risk of Diabetic Retinopathy Progression over 4 Years. Ophthalmology 2015.



Optos plc
Tel: +44 (0)1383 843350
ics@optos.com

Optos, Inc.
Tel: 800 854 3039
Tel: 508 787 1400
usinfo@optos.com

Optos Australia
Tel: +61 8 8444 6500
auinfo@optos.com

