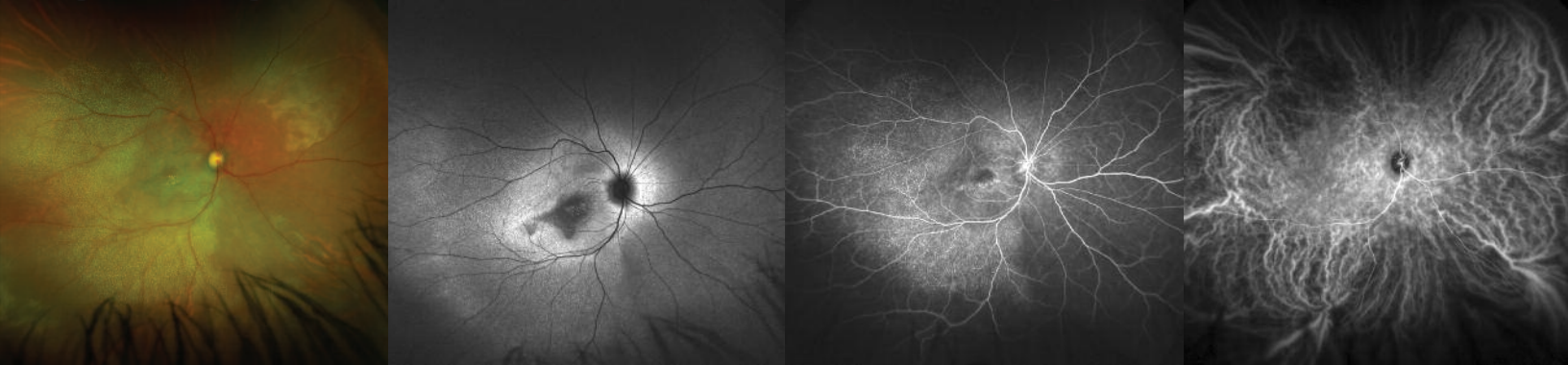


optomap

CLINICAL APPLICATIONS AND FUTURE TRENDS



A comprehensive review published in *Retina* describes how ultra-widefield (UWF) is evolving to become the standard of care imaging modality for many diseases and is finding new clinical and research applications such as for screening and telemedicine.

optomap facilitates the non-mydratric acquisition of 200° images of the retina. Over the last decade, UWF has greatly enhanced our realization of the importance of the peripheral retina and its vasculature in a variety of conditions. Multi-modality images are able to be captured including color (red and green), fundus autofluorescence (**optomap af**) fluorescein angiography (**optomap fa**) and indocyanine green angiography (**optomap icg**).

optomap color imaging has been validated in several studies finding sensitivity and specificity to be similar to traditional retinal photographs but additional information provided about the health of the periphery. These benefits have been evaluated for telemedicine programs, diabetic retinopathy, retinal breaks and tears, pediatric retinal disease, myopia, ocular oncology, inflammatory disease and a variety of vascular and inherited retinal disorders.

The clinical utility of **optomap af** has recently become apparent with studies demonstrating the high prevalence of peripheral autofluorescence changes in AMD, uveitis, retinal dystrophies, and CSCR.

“With exciting new clinical applications on the horizon, UWF imaging will likely become the standard of care not only for diagnostic purposes but also for screening, telemedicine, and perhaps even treatment.”

RETINA 2016¹

optomap fa has been found to be superior to ETDRS demonstrating angiographic abnormalities in multiple studies in eyes with diabetic retinopathy; has reported benefits in patients with retinal vein occlusion (RVO), sickle cell disease, antiphospholipid antibody syndrome, beta-thalassemia, Takayasu’s arteritis, Muscular Dystrophy, Susac’s Syndrome, HELLP, retinal detachment, myopia, retinopathy of prematurity (ROP) and oncology.

Recent studies using **optomap icg** demonstrate its diagnostic utility in a variety of disorders, including central serous chorioretinopathy (CSCR), uveitis, and age-related macular degeneration (AMD).

See how **optomap** will help you manage your patients.

For more information call **800-854-3039** or email **BDS@optos.com**

Building *The* Retina Company



optos.com

References:

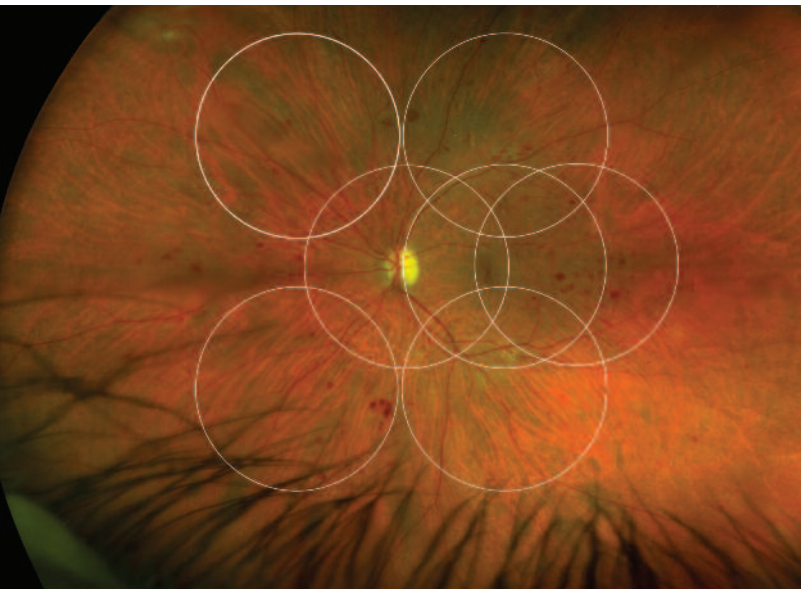¹ Nagiel et al ULTRA-WIDEFIELD FUNDUS IMAGING A Review of Clinical Applications and Future Trends *RETINA* 2016

CLINICAL SUMMARY

ULTRA-WIDEFIELD FUNDUS IMAGING: A Review of Clinical Applications and Future Trends

Nagiel, Lalane, Sadda, Schwartz
RETINA - 2016

- Several studies have compared **optomap** color images of diabetic retinopathy with the clinical examination, two-field and seven-standard field photography. Most studies comparing UWF with traditional photographs have determined the sensitivity and specificity to be similar but with additional peripheral information provided by UWF imaging.
- Another retrospective study found that more than 70% of eyes with AMD have peripheral abnormalities detectable on **optomap** and **optomap af**.
- **optomap fa** has been found to be superior to ETDRS demonstrating angiographic abnormalities in multiple studies in eyes with diabetic retinopathy. In eyes with central retinal vein occlusions, UWF FA seems to be a reliable modality for detecting macular leakage and ischemia in addition to peripheral nonperfusion.
- Another study of eyes with Behcet retinal vasculitis found that **optomap fa** detected active vasculitis not otherwise detectable in 85% of eyes, which prompted a change in management in 80% of patients.
- UWF imaging can in some cases provide a more precise documentation of the extent of retinal detachment compared to indirect ophthalmoscopy and provides an efficient way for the vitreoretinal surgeon to record the outcomes of surgical interventions as well as for counseling patients regarding their condition.
- **optomap** imaging represents an alternative method for documenting pediatric retinal pathology in an outpatient setting, obviating the need for an examination under anesthesia in some circumstances.
- Using **optomap af**, Pang et al found that 57% of eyes with CSCR had peripheral autofluorescence changes undetectable by clinical examination and 49% of eyes had gravitational tracks or gutters signaling past or present fluid movement from the macula to the inferior periphery.
- **optomap icg** demonstrated the presence of engorged choroidal vessels from the posterior pole to the vortex vein ampullae in over 80% of eyes with CSCR.
- Currently, the Optos is being increasingly used for UWF imaging of retinal and choroidal lesions owing to the increased field of view and its multimodal capabilities.
- Over the last 10 years, the Optos camera has undergone numerous technological improvements and been used effectively in an increasing number of clinical settings. Optos introduced a stereographic projection software algorithm to correct for the peripheral distortion and yield images which maintain the same angular relationship at every eccentricity. The accuracy of the measurements derived from this software has been validated in eyes containing prosthetic implants of known sizes.



optomap color image of diabetic retinopathy demonstrating the field captured by ETDRS 7-standard field and the peripheral lesions that would be missed.

Optos plc
Tel: +44 (0)1383 843300
ics@optos.com

Optos, Inc.
Tel: 800-854-3039
usinfo@optos.com

Optos Australia
Tel: +61 8 8444 6500
auinfo@optos.com

 **optos**[®]
optos.com