

Comparison the Optos P200C and Topcon TRC-NW6S in the screening of diabetic retinopathy



Pournaras J-A C,^{1,2} Erginay A,¹ Gaudric A,¹ Massin P.¹

¹Ophthalmology Department, Lariboisière Hospital, Assistance Publique-Hôpitaux de Paris, Paris 7 University, Paris, France; ²Jules Gonin Eye Hospital, University of Lausanne, Lausanne Switzerland

Introduction

In industrialized countries, diabetic retinopathy represents a major cause of blindness, principally due to late management. Diabetes causes silent progressive alterations leading to late symptomatic ocular complications. Systematic screening of diabetic patient could be efficient in the management of retinopathies.^{1,2,3}

Purpose

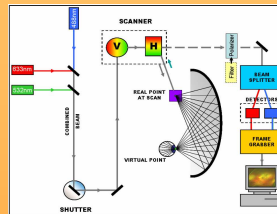
The purpose of the study was to compare the images taken by the Optos P200C and Topcon TRC-NW6S for diabetic retinopathy (DR) screening.



Material and Methods

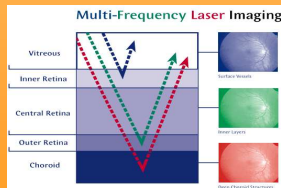
The OPTOS P200C (Optos, Scotland, United Kingdom) Scanning Laser Ophthalmoscope produces a high-resolution, ultra-widefield image of up to 200° or approximately 82 % of the retina in a single capture without pupil dilation.

The basic principle of SLO operation consists in a low powered laser beam that is scanned in two dimensions over the retina.



The instrument uses the combined **red** and **green** lasers for color imaging and both lasers follow the same optical path. Light reflected from the retina is detected and transformed into a digital computer image.

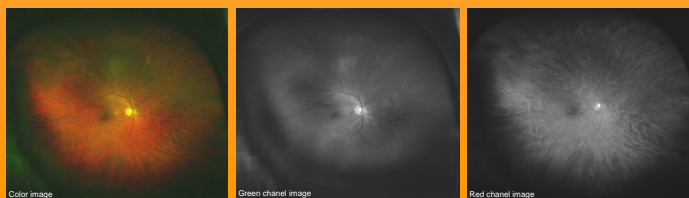
These two laser wavelengths penetrate the retinal structures to different degrees, each wavelength providing information for interpretation and diagnosis.



The blue channel (Laser - 488nm) is used in the Angiography mode to capture the sequence of images as the fluorescein dye enters the retinal vessels.

The Green Channel (Laser - 532nm) image contains information from the sensory retina through the pigment epithelium layers of the retina.

The Red Channel (Laser - 633nm) image contains information from the deeper structures of the retina, from the pigment epithelium through the choroid.



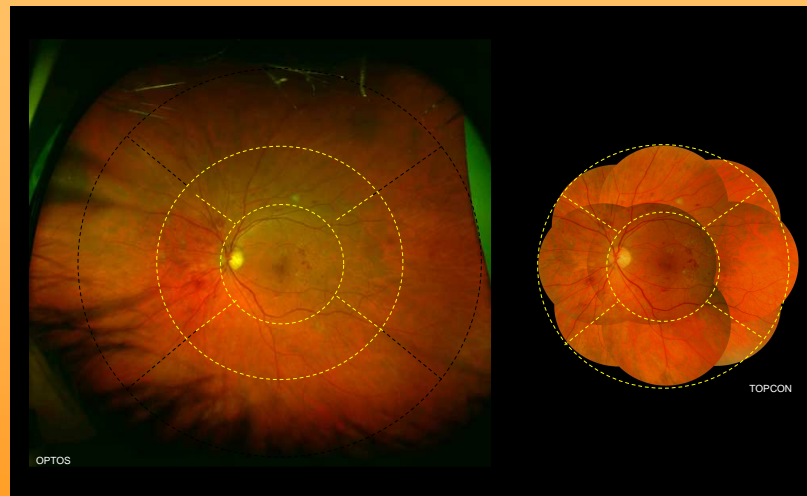
Material and Methods

Topcon TRC-NW6S produces high resolution images. The camera features eight peripheral fixation points as well as a built-in standard central fixation point, providing good reproducibility. The main optical system incorporates a dual magnification mechanism to allow for digital video capture of either 45° or 30° fields.

Procedure

- In 35 diabetic patients (68 eyes), one widefield image without dilation by Optos and 9 field images after dilation by Topcon were taken in both eyes.
- Images were assessed by two ophthalmologists for
 - quality (*Good, Fair, Insufficient*); the far and mid periphery were evaluated separately for Optos
 - DR
 - Maculopathy.
- The present study was performed according Helsinki principles and informed consent was signed by every patient

Results



Agreement for diagnosis between the two imaging devices was 100%.

Both retinographs detected in	Optos	Topcon
10 eyes	No DR	No DR
4 eyes	mild non-proliferative DR (NPDR)	mild non-proliferative DR (NPDR)
17 eyes	moderate NPDR	moderate NPDR
19 eyes	severe NPDR	severe NPDR
18 eyes	proliferative DR	proliferative DR
23 eyes	diabetic maculopathy	diabetic maculopathy

Image quality

Posterior pole image quality

	Good		Fair	
	eye (%)	eye (%)	eye (%)	eye (%)
Topcon	53 (78 %)	15 (22 %)		
Optos	64 (94 %)	4 (6 %)		

Image quality for the periphery

	Optos		Topcon	
	Good eye (%)	Fair eye (%)	Good eye (%)	Fair eye (%)
Superior field	62 (90%)	7 (10%)	60 (87%)	9 (13%)
Inferior field	64 (93%)	5 (7%)	57 (83%)	12 (17%)
Temporal field	67 (97%)	2 (3%)	59 (86%)	10 (14%)
Nasal field	66 (96%)	3 (4%)	58 (84%)	11 (16%)

Image quality for the far periphery taken only with Optos

	Good eye (%)	Fair eye (%)
Superior field	25 (37%)	43 (63%)
Inferior field	42 (62%)	26 (38%)
Temporal field	58 (85%)	10 (15%)
Nasal field	62 (91%)	6 (9%)

Conclusions

- Agreement for diagnosis between two retinographs was 100%.
- The performance of the Optos P200C in this study was highly satisfactory.
- With rapid, non-dilated examination of almost the entire retina it performs well as a screening device for diabetic retinopathy.
- The extreme peripheral view provided by the Optos device had no impact on the resultant DR grading assigned to the eye, despite additional lesions being detected.
- Bad quality of images in the extreme superior field related to lid can be avoided by attaching the lashes to the brow with adhesive tape.

References

- Chakravarti R, et al. Benefits of Optos(R) - a noncontact retinal scanner for diabetic retinopathy - a retrospective study in the reference hospital centers. *Diabetes Metab* 2010; 26: Apr - 4
- Agarwal E, et al. The five year incidence of blindness after introducing a screening programme for early detection of treatable diabetic retinopathy. *Diabet Med* 1993; 10:555-8.
- Hemrcusson M, et al. Incidence of blindness and visual impairment in diabetic patients participating in an ophthalmological control and screening programme. *Acta Ophthalmol Scand* 1998; 74:232-6.