

Comparison of Traditional versus Targeted Ophthalmoscopy Using P200C Scanning Laser Ophthalmoscope, Pilot Study

Presented at the 2009 Annual Meeting:
Kristen Brown, OD; Jeanette Sewel, OD
and Tom Trivison, PhD



Optometry's
MEETING®

June 24-28, 2009

“Targeted ophthalmoscopy, or detection and assessment of retinal lesions before BIO, may improve efficiency of a traditional fundus examination”

Kristen Brown, O.D. FAAO^{1,2}, Jeanette Sewell, O.D.^{1,2}, Tom Trivison, PhD³

¹New England Eye Institute, Boston MA; ²New England College of Optometry, Boston MA, ³New England Research Institute, Watertown MA

Introduction

Preventative care and screening for vision-threatening eye disease saves vision and money.^{1,2} Traditional (dilated) ophthalmoscopy to screen for eye disease however, is performed during routine exams only 6% of the time.³ The Panoramic 200C is a new scanning laser ophthalmoscope which takes non-mydratric 200-degree digital retinal images in <0.25 seconds. Up to 80% of the retina may be viewed in one image.

Purpose

The P200C SLO may be a valuable screening tool for the detection of retinal lesions in an efficient and comfortable manner for patients. Review of the digital Optomap images to guide the exam (called targeted ophthalmoscopy), may enhance the detection of retinal lesions. A pilot study was conducted to determine the sensitivity and specificity of the P200C SLO in detection of retinal lesions as compared to traditional and targeted ophthalmoscopy.

Methods

Forty subjects (65% female, 35% male) age 58.4 +/- 14.6 years underwent non-mydratric imaging with a P200C SLO. After dilation, subjects underwent traditional ophthalmoscopy and targeted ophthalmoscopy. The traditional exam consisted of BIO and slit lamp biomicroscopy with fundus lenses. In targeted ophthalmoscopy, Optomap images were used to guide the fundus examination. A satisfaction survey assessed patient perception of the technology and information provided by Optomap images. A masked Reader graded the images of all subjects. Retinal lesions were categorized into 3 regions: Optic Nerve, Macula/Posterior Pole and Mid-to-Peripheral Retina. 28 of the 40 subjects were examined by a retinal specialist who served as gold standard.

Results

Sensitivity and specificity of the Reader, the Traditional exam and the Targeted exam were computed in comparison to lesions identified by the gold standard (Table 1, 2). The patients satisfaction survey found that 92.3% of subjects believe that using cutting edge technology to examine their eyes is very important. 86% were very satisfied with the quality of technology used and the information provided by seeing images of their own eyes.

Table 1: Sensitivity of Reader (image alone), Targeted and Traditional exam in detecting lesions observed by a retinal specialist (gold standard)

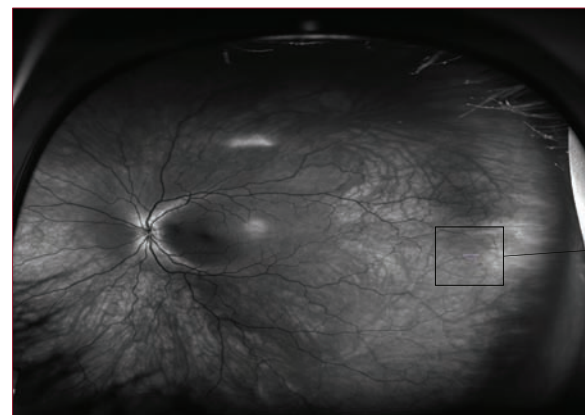
OD Region	Reader	Targeted	Traditional
Optic Nerve	79% (15/19)	84% (16/19)	68% (13/19)
Macula	73% (24/33)	91% (30/33)	64% (21/33)
Mid-Peripheral	69% (29/42)	88% (37/42)	50% (21/42)
OVERALL	72.3% (68/94)	88.3% (83/94)	58.5% (55/94)

OS Region	Reader	Targeted	Traditional
Optic Nerve	83% (15/18)	72% (13/18)	50% (9/18)
Macula	71% (22/31)	94% (29/31)	61% (19/31)
Mid-Peripheral	72% (34/47)	91% (43/47)	55% (26/47)
OVERALL	74.0% (71/96)	88.5% (85/96)	56.3% (54/96)

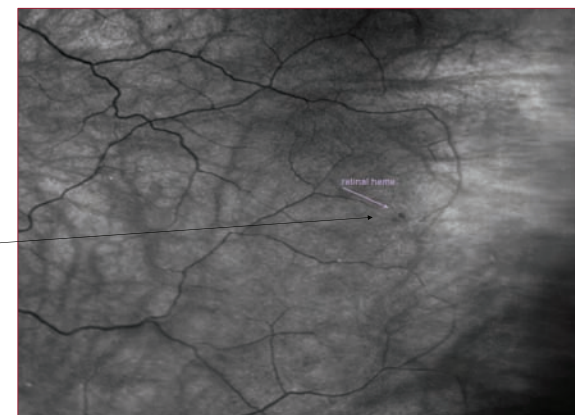
Table 2: Specificity of Reader (image alone), Targeted and Traditional exam in detecting lesions observed by a retina specialist (gold standard)

OD Region	Reader	Targeted	Traditional
Optic Nerve	98% (91/93)	97% (90/93)	98% (91/93)
Macula	98% (133/135)	98% (133/135)	98% (132/135)
Mid-Peripheral	91% (192/210)	96% (201/210)	92% (194/210)
OVERALL	95% (416/438)	96.8% (424/438)	95.2% (417/438)

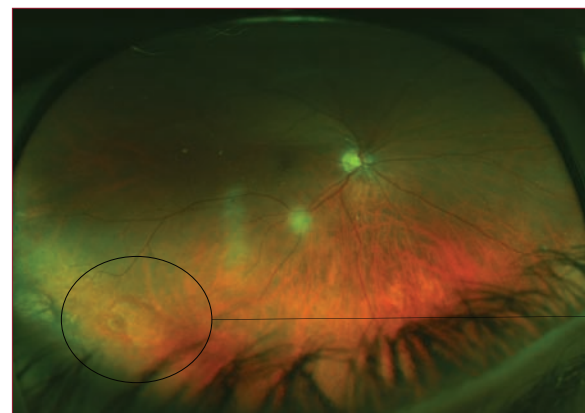OS Region	Reader	Targeted	Traditional
Optic Nerve	99% (84/86)	97% (83/86)	94% (81/86)
Macula	96% (120/125)	94% (118/125)	93% (116/125)
Mid-Peripheral	96% (180/187)	91% (171/187)	91% (170/187)
OVERALL	96.5% (384/398)	93.5% (372/398)	92.2% (367/398)



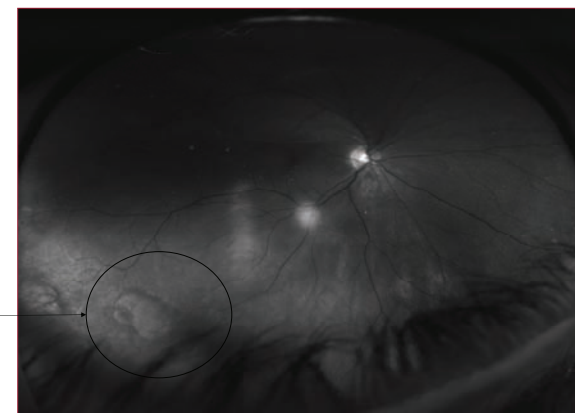
Small peripheral retinal hemorrhages observed in 32 year-old female study subject



Software enhanced view of same hemorrhages observed during targeted ophthalmoscopy



Small round peripheral retinal hole with detachment in asymptomatic 62 y/o patient



Software enhanced view of same retinal hole observed during targeted ophthalmoscopy

Discussion

Results suggest that overall sensitivity of the Reader (image review alone) was greater than Traditional ophthalmoscopy by 13.8% OD and 17.7% OS while overall sensitivity of Targeted ophthalmoscopy was greater than Traditional ophthalmoscopy by 29.8% OD and 31.2% OS.

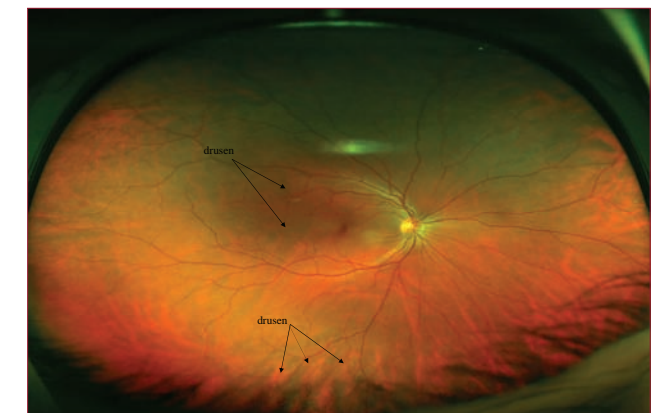
Conclusions

The P200C SLO may be a valuable screening tool in the detection of retinal lesions. Targeted (Optomap-guided) ophthalmoscopy may enhance the detection of lesions. Patients appreciate the use of advanced technology and the information provided by seeing images of their own eyes. Given the small number of subjects in this study, sensitivity and specificity are subject to error and should be interpreted with caution. A statistically powered study is underway.

References

- Javitt JC, Aiello L. Cost effectiveness of detecting and treating diabetic retinopathy. *Ann Intern Med* 1996;124:164-9
- Javitt JC, Aiello LP, Chiang Y, et al. Preventative eye care in people with diabetes is cost saving to the federal government. Implications for health care reform. *Diabetes Care* 1994;17:909-17
- Parisi ML, et al. Comparison of the effectiveness of a non-dilated versus dilated fundus examination in the pediatric population. *Journal AOA* 1996;67:266-72

Optos provided funding for this pilot study



Central and peripheral drusen observed in 48 year-old male study subject