Glaucoma/Stargardt's

Jerome Sherman, O.D., F.A.A.O.
Eye Institute and Laser Center
New York, NY

Introduction

We recently had the P200®C installed in our busy uptown office of our private practice for evaluation. We present below a case study which demonstrates the value of ultra-widefield, ultra-high resolution imaging for following patients with either central pole or peripheral pathology. In this case, Glaucoma and Stargardt's disease was diagnosed.

Patient History

A 37-year-old Hispanic female presented 5 years ago with a 20-year history of an "untreatable" retinal degeneration. At presentation, with high plus reading glasses, our patient was able to read magazine print at about 4 inches, but with some difficulty, and felt that her ability to read was worsening. The patient also complained of difficulty seeing at night.

Discussion

Best corrected visual acuity was 10/400 in each eye. Goldmann IOP's were 23 OD and 24 OS. Analysis of one of the P200®C images in each eye explains her visual difficulties. Further testing was performed; Pachymetry was 498u OD and 505u OS. Threshold fields revealed central Scotomas about 15 degrees in size OU, but fixation was erratic. Flash ERG's were normal and hence ruled out an overall retinal degeneration such a Retinitis Pigmentosa (RP) Inversa.

The pisciform flecks and the appearance of the macula define the full presentation of Stargardt's disease. Since the Flash ERG was normal, we need to consider a diagnosis other than RP to explain her peripheral and night vision problems. Another important observation is that the discs appear to have asymmetric cupping, and hence Glaucoma is obviously indicated. High IOP's support the diagnosis.

Conclusion

Although the patient is dilated yearly, **opto**map® images are obtained twice a year when the patient is not dilated and allow us to monitor for change in the posterior pole as well as in the mid and far peripheral retina in a highly efficient manner. We have seen patients with similar night vision problems and an analysis of the **opto**map® images has revealed subtle pigmentary clumping around vessels that were overlooked ophthalmoscopically. ERGs in such cases are quite reduced and delayed and confirm a diagnosis of RP.

The ability to capture in one ultra-high resolution image, the total extent of the damage to the retina caused by the two conditions in this case, is unique to the Optos® imaging platform contained within the P200®C.

optos®

DISCOVER • DIAGNOSE • DETERMINE

Optos plc is a leading and rapidly growing medical technology company for the design, development, manufacturing and marketing of devices that image the retina. The Company has gained regulatory clearance (CE and FDA 510(k)) to market its third device - P200®C. The P200®C is aimed at practices looking for advanced clinical capabilities. With a view up to 82% of the retina in a simultaneous, single image, Optos' technology provides an unequalled combination of wide-field retinal imaging, speed and convenience for both practitioner and patient.

optomap® *plus* with P200®C

optomap® *plus* image of left eye. Numerous pisciform flecks throughout the retina and maculopathy-characteristic of Stargardt's disease. Also seen are several large floaters.

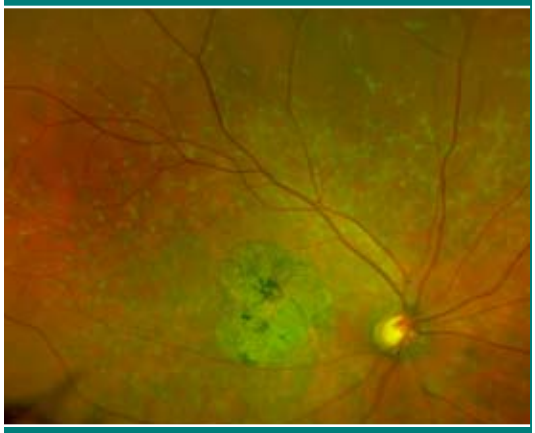

ResMax™ image of right eye. In this view the "beaten bronze" appearing maculopathy characteristic of Stargardt's and a large cup typical of Glaucoma are clearly viewed.

Zoomed view of ResMax™ image of left eye. In addition to the maculopathy and the shadow of the floater, the disc exhibits a large cup and an inferior notch.

WWW.OPTOS.COM