

optomap® LEADS TO DIAGNOSIS OF **MELANOMA** AND **DIABETIC RETINOPATHY** IN HUSBAND AND WIFE

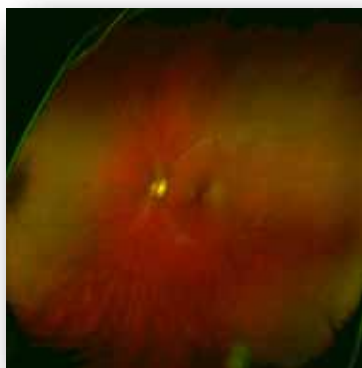


Summary: Middle-aged couple Jack and Peggy Anderson both received startling news on the same day during routine eye examinations with Dr. Michael Goldsmid in San Diego. The **optomap** images showed signs of conditions later diagnosed as malignant melanoma and worsening diabetic retinopathy, respectively – both had serious implications. But, thanks to the **optomap** and Dr. Goldsmid's persistence, both Peggy and Jack were able to pursue early treatment, which made all the difference in their outcomes.

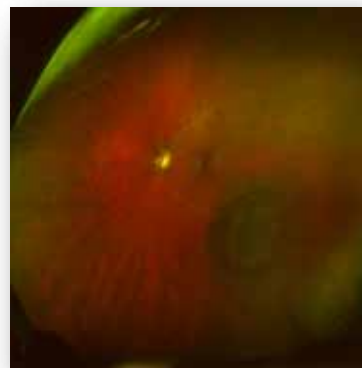
Jack, a neonatologist, had an **optomap** several years prior as part of his pre-LASIK workup and, at the time, everything appeared normal. On this day, however, the **optomap** image of his left eye showed a possible choroidal melanoma – a potentially life threatening condition. Without early detection and treatment, approximately half of patients with choroidal melanoma will die within 10 years due to metastasis to other parts of the body.

Perhaps most interesting in this case is that, while the melanoma was visible in the **optomap**, it was not that apparent in the traditional portion of the retinal exam. Beyond the diagnosis, **optomap** played an important role in patient education. Dr. Goldsmid could show Jack the difference in his **optomap** images from 2002 and his image that day and Jack instantly grasped the severity of what they were seeing. Jack was referred to the prestigious Wills Eye Institute in Philadelphia where he received a diagnosis and radiation therapy.

(cont'd)



Jack's 2002 **optomap**



Jack's **optomap** showing choroidal melanoma

optomap[®] LEADS TO DIAGNOSIS OF **MELANOMA** AND **DIABETIC RETINOPATHY** IN HUSBAND AND WIFE

cont'd

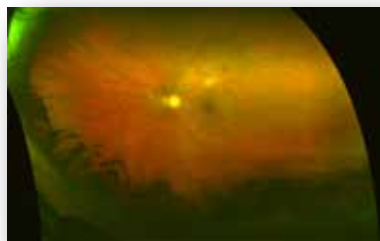Thanks to the findings in the **optomap**, the malignant melanoma was diagnosed and treated at a relatively early stage. Jack still has full vision in both eyes. He does, however, have a 50% chance of losing vision in his left eye in 3-5 years from the radiation damage. He is regularly monitored, as he has a 10% chance of getting metastases to the liver or chest. Yet, if the melanoma had not been detected early on, the chances of metastasis would have been significantly higher.



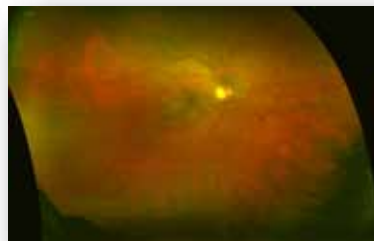Peggy, a registered nurse, thought she was successfully managing her Type 2 diabetes and had been told by her retinal specialist that her condition was improving. However, that day at Dr. Goldsmid's office, her **optomap** images showed otherwise. Her retinopathy was advancing to a point where it could negatively affect her vision, even while she was diligently following her diabetes regimen. Peggy was immediately referred to her endocrinologist and retinal specialist.

Dr. Goldsmid tenaciously encouraged Peggy to visit her specialists repeatedly. She eventually received retinal laser treatment and was able to retain 100%

of her vision. Peggy has resumed her normal activities and is still going for eye exams every two months with periodic laser procedures.



*Peggy's left eye **optomap** showing diabetic retinopathy*



*Peggy's right eye **optomap** showing diabetic retinopathy*

Peggy now actively lectures to medical students on the value and importance of eye exams, advocating the use of **optomap** technology whenever possible. And as might be expected, the Andersons have provided Dr. Goldsmid with multiple referrals.

optomap images courtesy of Dr. Goldsmid

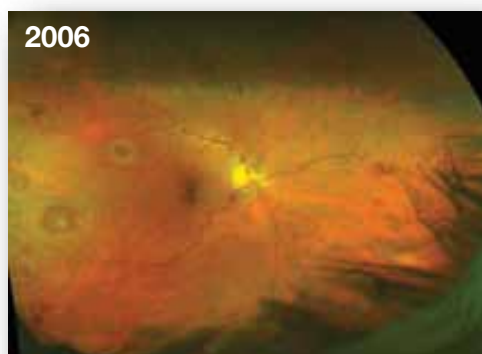
optomap[®] FACILITATES DETECTION OF LEUKEMIA IN PATIENT WITH NO OUTER SYMPTOMS

Summary: *This 59-year-old patient was seemingly in good health with no signs of illness, but an **optomap** retinal image during a routine eye exam indicated otherwise. The image revealed hemorrhages in her retina. Her physician closely examined the image, concluding that what he saw could be related to a more serious condition. The patient was eventually diagnosed with myelogenous leukemia. Early diagnosis, thanks to the **optomap**, has helped her to make a marked recovery.*

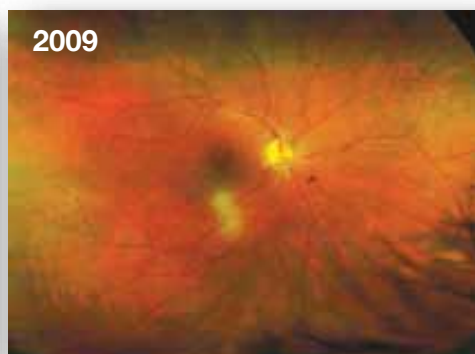Fifty-nine-year-old “Emma” was optimistic about her health when she stepped into Dr. Elaina Groo’s office in Newburg, New York for a routine eye exam. She had no signs of illness, though Dr. Groo found that Emma’s vision had deteriorated since her last exam. During the subsequent comprehensive 14-point eye exam, which included an **optomap** evaluation of the retina, Dr. Groo observed that Emma had two major eye hemorrhages and a few smaller ones as well. Based on the **optomap** images, the doctor suspected that the eye hemorrhages could have been secondary to a blood abnormality, which could indicate various anemias and leukemias. She referred Emma to a retinal specialist who determined it to be chronic myelogenous leukemia (CML). Emma was then referred to her internist, and then on to an oncologist for treatment.

Emma began treatment for the leukemia in May of 2006. She has shown marked improvements in her **optomap** images, as well as in her overall health. She has continued to receive **optomap** exams as a way to monitor the progress of her treatment.

From the initial exam to the leukemia diagnosis by the specialist to the referral to the oncologist, **optomap** technology accompanied Emma through this entire process. Dr. Groo and Emma both agree that the ultra-widefield view of the **optomap** contributed to the early detection of the disorder. Being able to view the dramatic improvements in her eyes has encouraged Emma to continue with the treatment program. In this case, the **optomap** was a critical tool for revealing hemorrhages leading to diagnosis. It was also an important part of patient education, ultimately encouraging confidence in the treatment.



Hemorrhages indicating blood dyscrasia



After treatment for leukemia

optomap[®] HELPS PHYSICIAN DIAGNOSE POTENTIALLY LIFE-THREATENING MELANOMA IN 8-YEAR-OLD

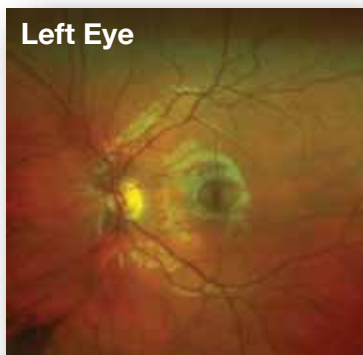


Summary: An 8-year old girl was diagnosed with malignant choroidal melanoma after an unusual dark area was seen in an **optomap** retinal exam. As a result of the early diagnosis, surgeons were able to successfully remove the tumor before it spread. The girl's mother credits the **optomap** with helping the doctor see a problem that, if left undetected, could have been fatal.

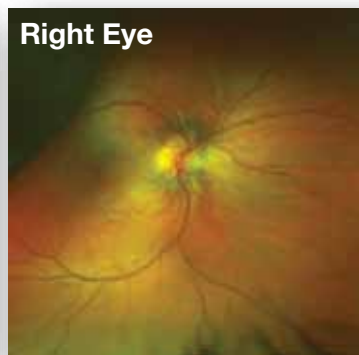
Eight-year-old Tori arrived at Dr. Thiele's office for her first eye exam with slightly blurred vision in one eye. Tori's parents were reluctant to have her eyes dilated because the process is often unpleasant, especially for children, making it difficult for the doctor to clearly view the back of the retina. When using **optomap** imaging, dilation is at the discretion of the eye care professional, so Dr. Theile ordered an **optomap** as part of the comprehensive eye exam. The images revealed a large retinal detachment; and based on Tori's age and the size of the detachment, Dr. Theile suspected that cancer was a possibility. He immediately referred her to Will's Eye Hospital for further evaluation. Tori's diagnosis was a retinal detachment caused by a malignant choroidal melanoma. Unfortunately, her eye had to be removed in order to eliminate the tumor, but had the cancer not been detected early, the consequences may have been much worse.

Tori will continue to be seen twice a year. Specialists are 99% certain that the eye was the primary lesion; however, she will need to be free of any cancer cells for the next 20 years before she is considered to be in full remission.

Tori's mother credits the **optomap** Retinal Exam for discovering the melanoma that, if undetected, could have been fatal. This demonstrates the importance of having an **optomap** every year, regardless of age. It is often difficult to do a thorough dilated exam on a child, and the **optomap** enabled Dr. Thiele to clearly see and identify the detachment and lesion.



Healthy left eye



Malignant choroidal melanoma and retinal detachment in 8-year-old